



**Japanese version of the terminology  
and the atlas of developmental  
abnormalities in laboratory species**

**Activities of Experimental Animal Terminology PJ  
in JTS Terminology Committee**

9<sup>th</sup> Berlin Workshop on Developmental Toxicology  
13-14 September 2018, Berlin

**Michio Fujiwara  
Drug Safety Research Labs  
Astellas Pharma Inc.**

# Activities of Experimental Animal Terminology PJ

## I. Promote appropriate use of version 2 in Japan

- Establishment and maintenance of the website database
- Provide recommendation for appropriate Japanese terminology
- Improvement of photographic images on the website
- Publishing “Atlas of Developmental Abnormalities in Laboratory”

## II. Guide appropriate toxicological evaluation using version 2 focused on rodent/rabbit embryo fetal development study (EFD)

- Conducting a survey to recategorize “gray zone” abnormalities which were not categorized into either “malformation” or “variation” in DevTox meetings
- Conducting a terminology workshop in the JTS annual meeting from 2015 to 2017
- Updating the website database with the results of recategorization
- Reporting through the journal Congenital Anomalies

# JTS Laboratory animal Congenital Anomaly Database

All the data are offered by THE JAPANESE TERATOLOGY SOCIETY

- External [Glossary](#) [AppendixA](#)
- Visceral [Glossary](#) [AppendixB](#)
- Skeletal [Glossary](#) [AppendixC](#)
- [AppendixD](#)
- [AppendixE](#)

next

問い合わせ先: 日本先天異常学会事務局 jts@ac-square.co.jp

Table 1 External Abnormalities

Version 3 (May 15, 2018)

Region / Organ / Structure	Observation	Synonym or Related Term	Non-preferred Term	Definition	Note	Ver. 1 Code No.	JTS Classification
General 全身	Subcutaneous edema 皮下浮腫	Generalized 全身性	<i>Anasarca</i> 全身性浮腫	An accumulation of interstitial fluid in subcutaneous connective tissue 皮下結合組織における間質液の貯溜		10001	Malformation or Non-structural abnormality
Conjoined twins 二重体		<i>Omphalocite</i> 臍帯寄生体 臍帯栄養児		Monozygotic twins with variable incomplete separation into two during cleavage or early stages of embryogenesis 卵割あるいは胚発生の早い時期に種々の程度で不完全に2つに分かれた一卵性双生児	Site and extent of fusion should be described 癒合の部位および範囲を記述する	10002	Malformation
Fetus or pup/neonate	Discolored 変色	<i>Skin discolored</i> 皮膚変色		Generalized or localized region of abnormal color (other than pale) 全身あるいは局所領域の異常色(蒼白以外)	See also "General-Fetus or pup/neonate Pale" and "General-Skin Discolored" JTS Comment: Difficult to be distinguished from changes by artifact. 「全身一胎児、出生児/新生児の蒼白」及び「全身一皮膚の変色」を参照 アーティファクトによる変化との見極めが困難 (JTS追記)	New	Not applicable
	Weight change 量(化)				Relative to normal JTS Comment: Recommended to be evaluated by the fetal body weight 正常と比較 体重による評価を推奨 (JTS追記)	New	Not applicable

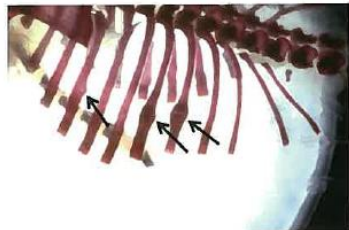
# Atlas of Developmental Anomalies in Experimental Animals

2-4 Absent head 頭部欠損 (Code No.: 10009, MP No.: 0009579)

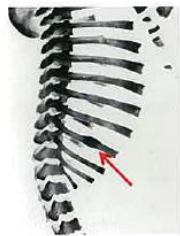Species	Rabbit
Memo	Absent head, Acephaly: Absence of the head 頭部欠損、無頭(症): 頭部が欠損している。左の胎児では、舌など一部の頭部・顔面組織がみられるが、頭部の大部分が欠損しており、頭部欠損(無頭)の範疇とする。



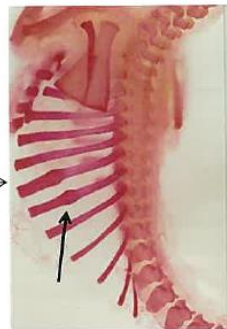7-9 Nodulated rib 肋骨結節状 (10633)



Species	Rabbit
Memo	Nodulated rib (arrow): Both focal enlargement and knobby are observed in this fetus. 肋骨結節状(矢印): 円形状(局所肥大)とノブ状が見られる。

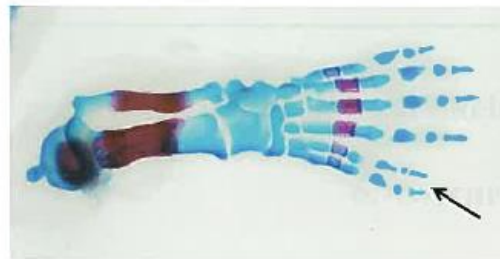

Species	Rabbit
Memo	Nodulated rib (arrow): The knobby type is observed in these specimens. 肋骨結節状(矢印): ノブ状の結節が見られる。

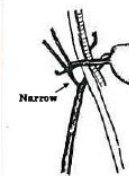
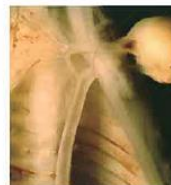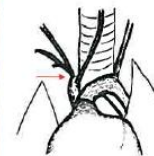

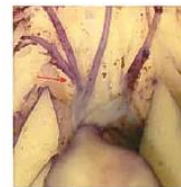
5-5 Supernumerary hindpaw phalanx 趾節骨過剰 (10866)

Species	Rat
Memo	Supernumerary hindpaw phalanx (pre-axial): The 1st phalanx is duplicated external observation. 趾節骨過剰: 軸前性の過剰(矢印)。外表では多趾(10088)。

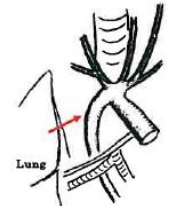
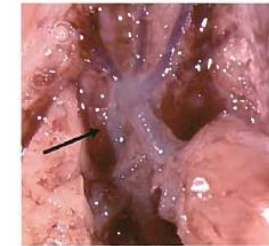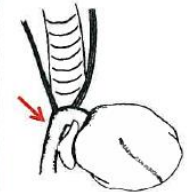

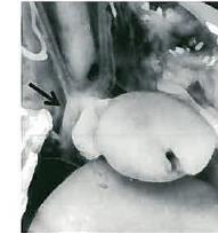
6-4 Retroesophageal aortic arch 食道背方大動脈弓 (1)



6-5 Right-sided aortic arch 右側大動脈弓 (10211)

Species	Rabbit
Memo	Right-sided aortic arch 右側大動脈弓



Species	Rat
Memo	subclavian artery origin (New, red arrow in Fig): The aortic arch passes behind the esophagus and trachea. 食道背方大動脈弓: 大動脈弓が食道及び気管の背側を走行し、血管輪を形成している。右鎖骨下動脈起始部位置異常(New、図中の矢印)を伴う。

Species	Rat
Memo	Retroesophageal aortic arch: The aortic arch is narrow and passes behind the esophagus and trachea. 食道背方大動脈弓: 大動脈弓が細く、食道及び気管の背側を走行し、血管輪を形成している。

# Results of recategorization of external “gray zone” anomalies in JTS

## 168 external findings in Version 2

**Categorized in 3<sup>rd</sup> , 4<sup>th</sup> and 8<sup>th</sup> DevTox Berlin-Workshop**

- 95 findings “Malformation”
- 73 findings “Gray zone” anomalies

**Recategorized 73 “gray zone” findings by Experimental Animal Terminology PJ in JTS Terminology Committee**

- 42 findings were categorized as malformation
  - 38 findings “Malformation”
  - 3 findings “Non-structural abnormality”
  - 1 finding “Malformation” or “non-structural abnormality”
- 31 findings “Not applicable” for fetal examination in rodent/rabbit EFD
- No “variation”
- No “gray zone”**